

**PATIENT**

Moe Jorgensen

**SPECIES**

Canine

**BREED**

Chihuahua Mix

**SEX**

Male Neutered

**AGE**

8 years

**WEIGHT**

17lbs

**INTERPRETED BY**

Maggie Machen  
 Lamy, DVM, DACVIM  
 (Cardiology)

**IMAGING PERFORMED BY**

Sara Hansen

**HOSPITAL NAME**

South Willamette  
 Veterinary Clinic

**REFERRING VET**

Dr. Willaman

**INVOICE**

23697

**DATE**

4/15/22

**PRESENTING CLINICAL SIGNS**

History: Pronounced cardiac murmur present from at least 1/2021. Has been asymptomatic until recently. Lags behind on walks and now has episodes of rapid breathing.  
 -Abnormal PE/Chem/CBC/UA Results: CBC, Chem 17 and HWT from 1/2021 were WNL with the exception of a mild increase reticulocytes.  
 -Sedation: Torb.

**ELECTROCARDIOGRAPHIC FINDINGS** \*Note: Single lead ECGs are evaluated as a rhythm strip. Morphology/MEA cannot be definitively commented on.

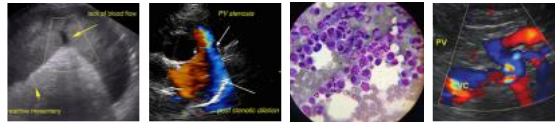
A single lead ECG is available; 50mm/s, 20mm/mV. The average heart rate is 150bpm (range 103-176bpm). The rhythm is sinus in origin, with a p for every QRS complex and vice versa. The P and QRS morphologies are positive. No ectopic beats, pauses or dysrhythmias observed.  
 ECG diagnosis: Normal sinus rhythm with respiratory variation.

**ECHOCARDIOGRAM FINDINGS**

2D, m-mode and Doppler imaging are available. Diffuse thickening of mitral valve leaflets (anterior > posterior) with prolapse into the left atrial lumen. Severe eccentric mitral regurgitation with marked left atrial dilation. Significant LV dilation with hyperdynamic myocardial function. The tricuspid valve appears mildly thickened, with mild tricuspid regurgitation. Mildly elevated velocity. Mild right atrial and ventricular dilation consistent with early pulmonary arterial hypertension. The pulmonic and aortic valves are normal in morphology and mobility. Normal pulmonic and aortic outflow velocities. No pulmonic or aortic insufficiency. No pericardial or pleural effusion noted. No cardiac tumors observed.

**CARDIAC CHART**

CANINE CARDIAC PARAMETERS	MR VMAX (m/s)	TR VMAX (m/s)	LA/AO (Boon method)	LA/AO (Heart Base; Swe)	FS (%)	EF (%)	EPSS (cm)
NORMAL PARAMETER	4.5-5.5	<2.7	1.3	<1.6	28-40	40-100	<0.6
PATIENT	5.6	2.9	1.75	2.5	45	77	0.2
CANINE CARDIAC PARAMETERS	HR (BPM)	AV VMAX (m/s)	PV MAX (m/s)	BODY WEIGHT (kg)	LA 2D short axis Base view (cm)	LVIDd Avg; 2D and m-mode short axis (cm)	LVIDs Avg; 2D and m-mode short axis (cm)
NORMAL PARAMETER	50-100	0.7-1.7	0.7-1.6	BELOW	BELOW	BELOW	BELOW
PATIENT	130	1.6	1.2	7.7	3.5	4.1	2.3
*Normal chamber parameters expressed as a mean value (SD)				3	1.27 (5.3)	2.46 (2.46)	1.36 (5.5)
<b>BODY WEIGHT DEPENDENT PARAMETERS</b>				5	1.40 (4.5)	2.74 (5.2)	1.60 (4.7)
Adapted from June Boon, Veterinary Echocardiography, 1998 Rishniw M and Hollis NE, J Vet Intern Med 2000; 14:429-435 Hansson et al, Vet Rad and Ultrasound 2002 Bonagura et al. Echocardiography: principles of interpretation, Vet Clin North Am 15:1177, 1995				10	1.50 (3.8)	3.27 (3.5)	2.06 (3.1)
				15	1.83 (2.0)	3.71 (2.4)	2.43 (2.1)
				20	2.02 (1.9)	4.14 (2.2)	2.80 (2.0)
				25	2.18 (2.4)	4.48 (2.9)	3.10 (2.5)
				30	2.33 (3.3)	4.83 (3.9)	3.39 (3.4)
				35	2.48 (4.3)	5.17 (5.0)	3.69 (4.5)



**PATIENT**

Moe Jorgensen

	40	2.62 (5.2)	5.48 (6.1)	3.96 (5.4)
	50	2.88 (7.1)	6.07 (8.3)	4.46 (7.4)

**SPECIES**

Canine

**BREED**

Chihuahua Mix

**SEX**

Male Neutered

**AGE**

8 years

**WEIGHT**

17lbs

**INTERPRETED BY**

Maggie Machen  
 Lamy, DVM, DACVIM  
 (Cardiology)

**IMAGING PERFORMED BY**

Sara Hansen

**HOSPITAL NAME**

South Willamette  
 Veterinary Clinic

**REFERRING VET**

Dr. Willaman

**INVOICE**

23697

**DATE**

4/15/22

**INTERPRETATION OF THE FINDINGS & FURTHER RECOMMENDATIONS**

The cause of the murmur is chronic degenerative valve disease causing severe mitral and mild tricuspid regurgitation. Marked left atrial enlargement indicates the risk for spontaneous congestive heart failure is elevated. Mild TR is also noted, with evidence of early pulmonary hypertension. No additional issues such as systolic dysfunction are identified. The ECG is unremarkable, with a normal sinus rhythm.

The described cough is likely multi-factorial in origin, including a mechanical component due to cardiomegaly, potential respiratory disease as well as early CHF given the severity of disease. Screening chest radiographs are recommended. Given the symptoms and echo findings, full lifelong cardiac support is recommended as below including Lasix therapy. Depending on clinical response to the medications, cough suppression may also be useful. Monitoring of sleeping breathing rates in the future will be paramount to determine the origin of any future cough. The average survival of canine patients with active pulmonary edema is 8-9 months on medications, however they generally are able to maintain a good quality of life for that period. Patient will always be at risk for recurrent CHF, development of arrhythmias/LA tear, syncope and/or sudden death in the future. Monitoring of renal values is recommended lifelong.

Omega fatty acid supplementation and mild salt restriction may also be of some long-term benefit. Monitor for development of a worsening cough, labored breathing, exercise intolerance or collapse episodes.

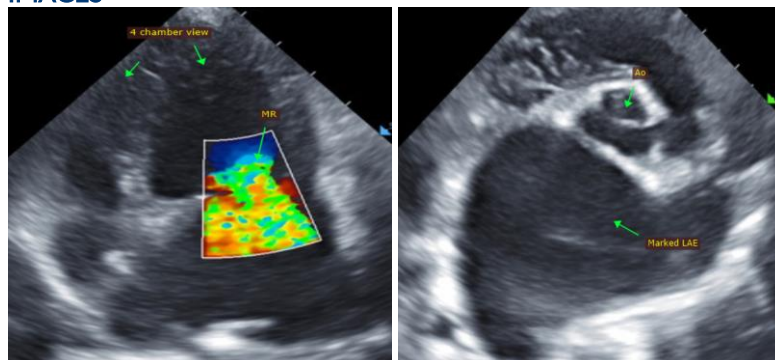
**PLAN**

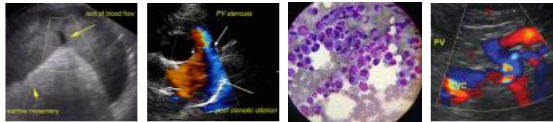
Screening BP and CXR are recommended. Administer Pimobendan 0.3mg/kg PO q12h. Administer low dose furosemide/Lasix 1 mg/kg PO q12h. Administer spironolactone 1-2mg/kg PO q12h. Consider hydrocodone with homatropine (0.2-0.4mg/kg PO up to q4-6 hours PRN) if cough persists despite normal SRRs.

A renal panel and BP are recommended in 10-14 days, then every 3-4 months on diuretics to ensure tolerance of medications. If doing well at that time and BP >130mmHg, institute ACEI 0.5mg/kg PO q12h.

A recheck echocardiogram is recommended in 6 months to screen for progression, sooner if clinical signs arise/persist.

**IMAGES**





**PATIENT**

Moe Jorgensen

**SPECIES**

Canine

**BREED**

Chihuahua Mix

**SEX**

Male Neutered

**AGE**

8 years

**WEIGHT**

17lbs

**INTERPRETED BY**

Maggie Machen  
Lamy, DVM, DACVIM  
(Cardiology)

**IMAGING  
PERFORMED BY**

Sara Hansen

**HOSPITAL NAME**

South Willamette  
Veterinary Clinic

**REFERRING VET**

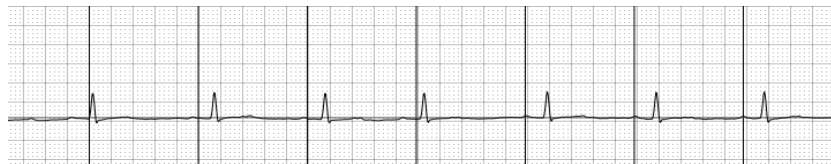
Dr. Willaman

**INVOICE**

23697

**DATE**

4/15/22



The information and recommendations provided are based on the images presented by the referring veterinarian. No evaluation can be communicated regarding pathology that was not visible in the image/video clips provided.

Thank you for this referral. This report was generated using transcription software, and minor dictation errors may be present. If the clinical or image interpretation does not parallel your findings or if I can be of any further assistance, please contact me.

**Maggie Machen Lamy, DVM**  
Diplomate of the American College of Veterinary Internal Medicine (Cardiology)  
info@sonopath.com